

# ConvaMax™ SUPERABSORBER



ConvaMax™ Superabsorber

## CASE STUDY COMPENDIUM

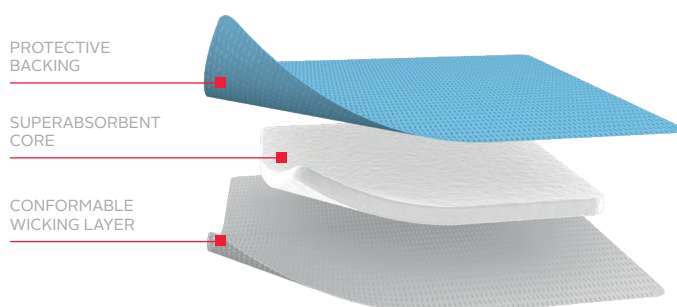
## PRODUCT INFORMATION

ConvaMax™ Superabsorber, an innovative dressing for moderate to highly exuding wounds that effectively locks away large amount of exudate including harmful bacteria and MMPs to promote wound healing<sup>1</sup>. ConvaMax is available in non-adhesive and silicone adhesive formats.


ConvaMax™ Superabsorber is a dressing designed to manage moderate to high levels of fluid and exudate<sup>1</sup>. The superabsorbent central pad absorbs exudate and forms a gel, locking it away in the core, preventing release back to the wound.

The protective blue backing minimises the risk of leakage and strikethrough of exudate into bandaging, clothing or bedding. The conformable wicking layer provides an interface with the wound and wicks fluid into the core.

### ConvaMax™ Superabsorber



### ConvaMax™ Superabsorber Adhesive



Dressing size	Pack size	Product code	PIP Code
<b>ConvaMax™ Superabsorber Non-adhesive</b>			
7.5cm x 7.5cm 3in x 3in	10	422566	414-8631
10cm x 10cm 4in x 4in	10	422567	414-8649
10cm x 20cm 4in x 8in	10	422568	414-8680
12.5cm x 12.5cm 5in x 5in	10	422569	414-8656
15cm x 15cm 6in x 6in	10	422570	414-8664
15cm x 20cm 6in x 8in	10	422571	414-8698
20cm x 20cm 8in x 8in	10	422572	414-8672
20cm x 30cm 8in x 12in	10	422573	414-8706
20cm x 40cm 8in x 16in	10	422574	414-8714

Dressing size	Pack size	Product code	PIP Code
<b>ConvaMax™ Superabsorber Adhesive</b>			
15cm x 15cm 6in x 6in	10	422579	414-8615
20cm x 20cm 8in x 8in	10	422581	414-8623

Reference: 1. In-Vitro Performance Characteristics of ConvaMax™, WHRI6045 MS161, Data on file, ConvaTec.



# ConvaMax™ SUPERABSORBER



## East Berkshire Wound Care Nurses & Windsor District Nurses

BERKSHIRE HEALTH FOUNDATION TRUST

### CLINICAL CHALLENGE

A difficult to dress, complex wound on an 86 year old man with a fungating tumour on his neck with high levels of exudate (Fig 1).

### THE PATIENT

Following his radiotherapy Mr. E was under the care of Practice Nurses. The wound required redressing twice a day and this process took up to an hour each time. The wound was being redressed with a foam dressing.

The number and duration of the dressing changes started to become exhausting for Mr. E and challenging for the Practice Nurses to maintain. As a result the District Nurses were asked to help, even though he didn't fit the home needs assessment criteria.

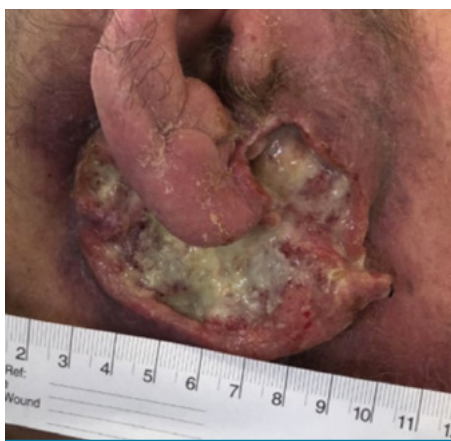

Fig 1. Wound on presentation

### THE WOUND

The wound, a malignant fungating tumour located on the neck had been static for 6 months prior to assessment. The wound was heavily exuding and would often leak having a significant impact on the quality of life for both Mr. E and his wife who would often become anxious and telephone the nurses for help.

The location of the wound made it challenging to dress and for that dressing to stay in place. Often the dressings impacted on his hearing or vision as they were difficult to secure.

### MANAGEMENT AIMS

Due to the type of wound, the ultimate goal is not healing as these wounds are palliative. The aim therefore is symptom management to improve the patient's quality of life.

These aims include:

- Manage the wound exudate and subsequently prevent maceration of surrounding skin
- Eliminate the need for twice daily dressings
- Enhance patient well being and give confidence of not leaking

“

It did what it says on the tin. It exceeded our expectations.

”

## MANAGEMENT

Previously the wound had been redressed daily by a nurse with AQUACEL®Extra™ dressing and Zetuvit® Plus, this would then be re-dressed later in that day by Mrs. E as the dressing leaked. After 3 days of this routine the Wound Care Nurse suggested switching from the Zetuvit® Plus dressing to the new ConvaMax™ dressing which was currently being evaluated in the area.

The periwound skin was prepared and protected using Sensi-care™ barrier film. The wound was redressed with layered AQUACEL®Extra™ dressing 5x5cm (x3 dressings) covered with a ConvaMax™ 15x15cm Adhesive dressing, hyper-fix was applied to help secure the dressing (Fig 2).

## OUTCOME

When the nurse came to review the wound the following day it was noted that the ConvaMax™ dressing could have stayed in place for longer as there had been no leakage. The frequency of dressing changes was reduced to alternate days.

ConvaMax™ dressing prevented leakage from the dressing and managed the wound effectively (Fig 3). The dressing stayed in place and Mr. E could move his neck freely without worrying his dressing would come loose or leak.

Mr. E had been able to use the ConvaMax™ dressing as it was being evaluated within the Trust, however there was concern that when the evaluation was finished that the dressing would no longer be available to him. Due to the experience Mr. E had with ConvaMax™ the CCG agreed for it to continue to be available to him.

**The reduction in the number and frequency of the dressing changes from twice daily to alternate days meant that Mr. E didn't spend hours having his dressing changed.**

This had a significant impact on his quality of life as he was confident that the dressing would stay in place, thereby not leak causing undue stress and worry to him and his wife.

The nursing team saved valuable time by visiting less and felt reassured they wouldn't receive a telephone call from Mr. E's wife about a strike through or leak.

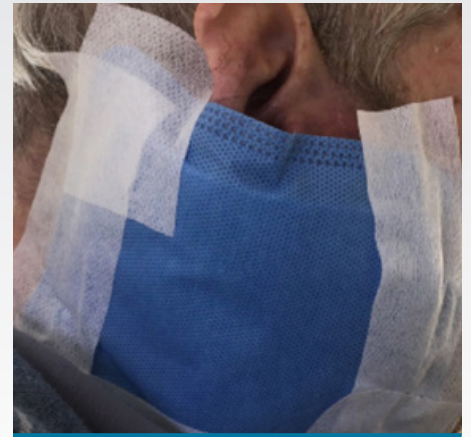

Fig 2. ConvaMax™ dressing in situ

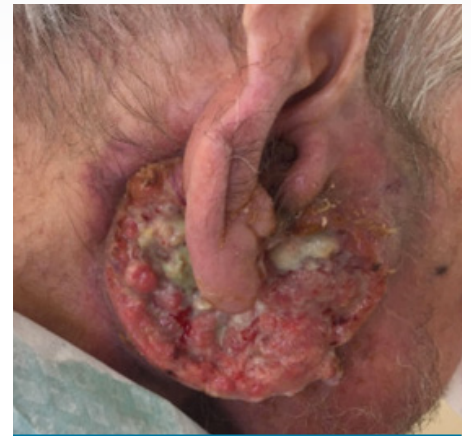

Fig 3. Wound 3 weeks post application of ConvaMax™ dressing

“

It made a huge difference to Mr. E and us. Please can it stay available for us to use.

”

# ConvaMax™ SUPERABSORBER



**Dr Albertini, General Practitioner**  
AVIGNON, FRANCE

## CLINICAL CHALLENGE

A non-healing leg ulcer with recurring infection, managed in an insulin-dependent diabetic with peripheral arterial occlusive disease (PAOD), associated with active smoking (Fig 1).

## CLINICAL CONTEXT

The presence of excess levels of exudate should always seek the underlying cause and treat accordingly. From a local wound perspective, good management of exudate remains a major focus to protect and preserve healthy periwound tissue and limit the impact on the quality of life of patients. The course of the wound remains dependent on the patient's response to the underlying aetiological treatment, their comorbidities, and general condition.

## THE WOUND

The wound presents as a deep cavity with fibrous tissue and excessive levels of exudate; the periwound skin shows signs of skin erosion, and inflammatory and painful characteristics. Despite a daily renewal of dressings, leaks are observed every day and strongly alter the quality of life (leaking of exudate onto footwear and bed sheets), and flows on the floor exposing to a risk of falling.

The previous dressing regime consisting of a highly absorbent foam dressing (Mepilex XT) and a superabsorbent dressing (Mextra) were not able to manage the abundant exudate production. Leakage from the dressing and skin sensitivity (Fig 1) supported a change in dressing selection.

## MANAGEMENT

AQUACEL® Extra™ dressing 20 x 24 cm folded in 2 + ConvaMax™ dressing 20 x 40 cm was applied (Fig 2). Daily change of dressings was justified to support wound progression by optimal management of the high levels of exudate and protection of the periwound skin.

## MANAGEMENT AIMS

- Improve exudate management
- Improve quality of life for the patient
- Improve the integrity of the periwound skin

“  
Significant skin  
improvement and  
intact dressings!  
”

## OUTCOME

- Comfortable local treatment protocol (trauma- and pain-free removal of dressing)
- Wound progression
- Excellent exudate management
- Improved quality of life
- Improved quality of the periwound skin (Fig 3).

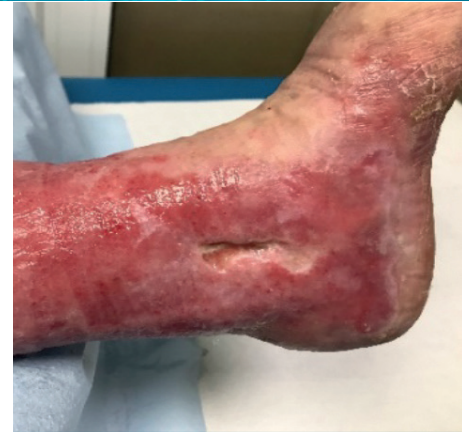

Fig 1. Wound prior to ConvaMax™ treatment

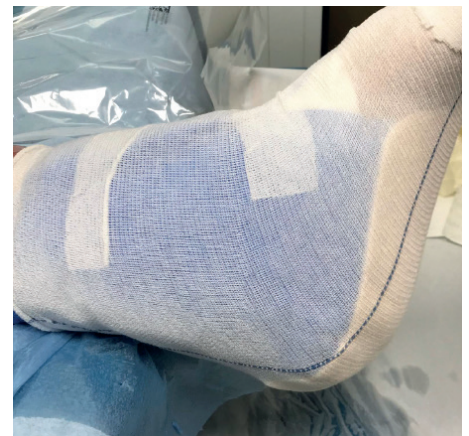

Fig 2. ConvaMax™ dressing in situ on 1st application

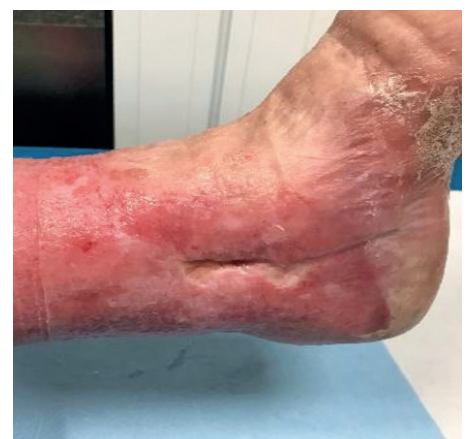

Fig 3. Wound 7 days after the start of AQUACEL® Extra™ dressing and ConvaMax™ dressing regime



# ConvaMax™ SUPERABSORBER



**José Miguel Gómez Coiduras, Wound Supervising Manager**  
**José Luis Malavé Álamo, A&E Nurse Expert in Complex Wounds**  
 HOSPITAL HLA EL ÁNGEL, MÁLAGA, SPAIN

## CLINICAL CHALLENGE

Plantar perforating disease in the left foot with 5 years duration (Fig 1). This disease is characterised by plantar ulceration associated with the duration of diabetes, poor glycaemic control often induced by neuropathy and/or arterial disease).

## THE PATIENT

A 72 year old male, moderate-severe dependence for activities of daily living (Barthel Index 40\*). Medical history: insulin-dependent type II Diabetes – poorly controlled. Elevated glycated haemoglobin, severe hypoglycaemic episodes. Hypertension. Chronic anaemia.

Evidence of Charcot neuroarthropathy. Previous amputation of all toes on the left foot and 4th right toe. Retinopathy (85% visual deficit) and diabetic nephropathy. Personal history of previous surgeries for recurrent urothelial carcinoma of the bladder, currently without treatment with Chemotherapy or Radiotherapy.

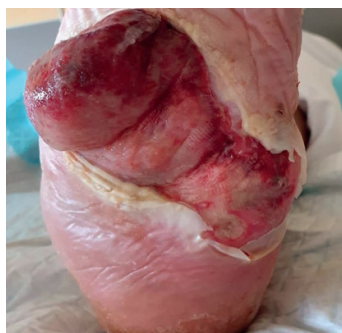
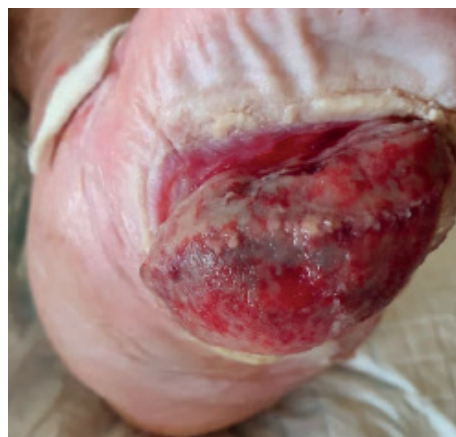
Fig 1. Wound prior to tissue mass removal

## THE WOUND

The wound is located on the mid-plantar aspect of the left foot (Fig 1).

Infection was evident with signs of purulent exudate accompanied by a foul odour draining from the lower region of the ulcerated area.

The wound culture was positive for *Pseudomonas aeruginosa*.

In addition, there was evidence of abnormal hypergranulated tissue in the upper region of the wound that caused dehiscence of the wound edges and protrusion of tissue mass extending from the wound bed to the outside of the wound bed. The presentation of the soft tissue mass caused suspicion of malignancy.

## MANAGEMENT AIMS

To ensure good management of exudate to protect the periwound skin, avoid complications in the complex patient and to extend the dressing wear time and reduce dressing change frequency over time.

“

The aim was to minimise the associated risks and avoid further amputation.

”

\* Collin C, Wade DT, Davies S, Horne V, The Barthel Index, Disability and Rehabilitation 2008, 10:2 61-63

## MANAGEMENT

### Treatment prior to tissue mass removal:

- Cleaning and disinfection with Polyhexanide betaine plus AQUACEL™ Ag+ Extra and secondary dressing with AQUACEL® Foam. Care and dressing change is performed every 48-72 hours depending on the exudate.
- Felt padding applied around the wound bed to help redistribute pressure away from the wound.

### Surgical removal of tissue mass

Biopsy results showed proliferation of a type of plantar fibromatosis characterized by the growth of hard and round or flattened nodules on the soles of the feet (Ledderhose disease) – no malignancy.

### Treatment post surgical

- Cleaning and disinfection with Polyhexanide betaine.
- Local treatment with corticosteroid cream to cease / slow down growth of fibromatous nodule and application of topical antibiotic therapy to manage bacterial load. (In line with local clinical protocol; alternating different active ingredients in order to avoid/reduce resistance).
- Increased and excessive levels of exudate production resulted in changing the dressing regime to application of AQUACEL™ Ag+ Extra in combination with ConvaMax™ Superabsorber as a secondary dressing (Fig 2). This combination also helped manage areas of the wound bed that were bleeding
- Care and dressing change every 48-72 hours depending on the exudate.
- Application of felt padding + support bandage.

### 3 - 12 weeks post tissue mass removal

The same pattern of care and dressing regime is maintained for 48-72 hours which supports:

- Control of exudate
- Reduced bleeding
- Bacterial load management
- Cessation / slowing down of fibromatous nodule
- Decrease of lesion size (Fig 3 and Fig 4).

## OUTCOME

The ConvaMax™ Superabsorber dressing allowed:

- Optimum control of excess exudate without maceration of the periwound skin
- Atraumatic removal of the dressing
- Comfort in carrying out daily living activities for the patient avoiding leakage of exudate to the outside of the dressing
- Management and superabsorption of exudate without saturating the dressing, resulted in extending the episodes of care from daily to dressing changes every 48-72 hours
- Positive progression in the healing process
- Significant reduction of the size of the wound (Fig 4).



Fig 2. ConvaMax™ dressing change every 48-72 hours

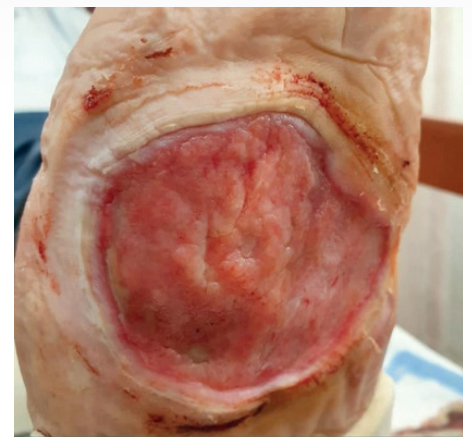

Fig 3. After 12 weeks of ConvaMax™ treatment

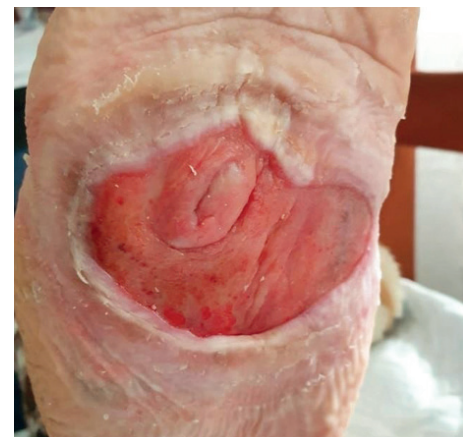

Fig 4. After 20 weeks of ConvaMax™ treatment

“  
Good management  
of the exudate has  
been crucial to achieve  
quality of life for  
the patient.  
”

# ConvaMax™ SUPERABSORBER



## Antonio Pomares Bonus, Nurse

C.S EL PLA, ELCHE, SPAIN

### CLINICAL CHALLENGE

Multiple heavily exudating venous vascular ulcers of 10 years duration, which have appeared and healed and subsequently broken down on several occasions. (Fig 1).

### THE PATIENT

A 79 year old male with reduced mobility. Clinical history of well-controlled type II diabetes mellitus, hypertension, atrial fibrillation, and hyperlipidaemia.

Medical intervention for varicose veins in both legs.

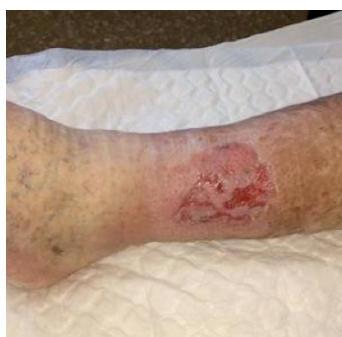
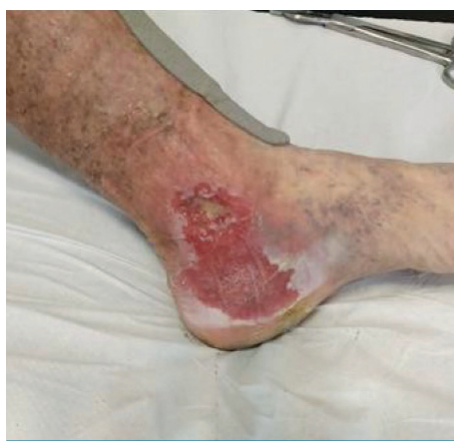
Fig 1. Injuries on the inside and outside of the left foot

### THE WOUND

Two wounds located on the Left Leg:

Wound 1 – located on inner (medial) aspect of the lower leg with a diameter of 2x2 cm.

Wound 2 – located on the outer (lateral) aspect of the leg with a diameter of 4x4cm.

Both lesions are heavily exuding of two years duration and have been treated in the health centre on several occasions since the patient performed ineffective self-care at home.

### MANAGEMENT AIMS

- Control of exudate
- Protection of the perilesional skin without maceration
- Bacterial load management
- Lesion size decrease
- Pain reduction

“

Control exudate to protect damaged perilesional skin and prevent from further injury.

”



## MANAGEMENT

### Current medication to control concurrent co-morbidities and complex medical history:

Metformin, Olmesartan + Amlodipine, Acenocoumarol, Doxazosin, Bisoprolol, Rosuvastatin + Fenofibrate.

Vascular ulcers previously treated with different therapeutic strategies such as: polymeric foams, hydrogels, alginates, hydrocolloid hydrofibre with silver, silver sulfadiazine, collagenase, etc.

Patient refuses compression therapy.

### Start of ConvaMax™ treatment regime (8 weeks duration):

Treatment with prior cleaning and disinfection with Polyhexanide betaine and ConvaMax™ Superabsorber non adhesive for appropriate exudate management (Fig 2).

- Local treatment with corticosteroid cream is applied in the perilesional area to relieve itching for 7 days in line with local protocol.
- Care is performed every 48-72 hours depending on exudate.
- Compression bandage applied from toe to knee.

The patient had previously refused compression therapy. His wounds had healed and broken down repeatedly over 10 years and affected his quality of life making him tired. The nurse explained and advised of the benefits to support improved outcomes and he changed his mind. His agreement to continue with the bandage therapy continued as he observed the wounds progress.

“

We controlled the exudate and prevented leakage and staining of clothes which allowed the patient to continue with his daily activities.

”

## OUTCOME

The ConvaMax™ Superabsorber dressing allowed:

- Optimum control of excess exudate without maceration of perilesional skin.
- Comfort in carrying out daily living activities for the patient avoiding leakage of exudate on to hosiery or clothing.
- Adequate management and super-absorption of exudate without saturating the dressing, spacing out care with dressing changes every 48-72 hours.
- Atraumatic removal of the dressing.
- Positive progression in the healing process.
- Significant reduction of the size of the wound (Fig 3 and Fig 4).
- Medial aspect of the leg: total closure in 6 weeks; outside of the leg: good progression of the wound until complete epithelialization 1 month later.

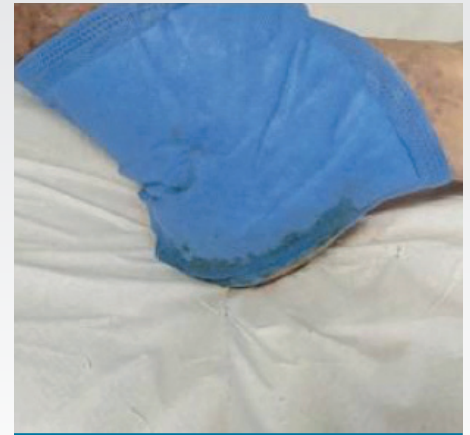

Fig 2. ConvaMax™ dressing in situ

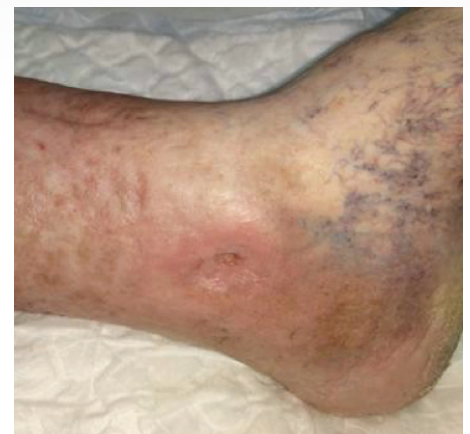

Fig 3. After ConvaMax™ treatment t (8 weeks duration)

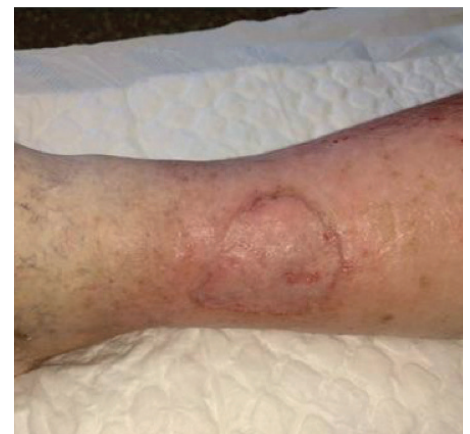

Fig 4. After ConvaMax™ treatment (8 weeks duration)



## Leanne Chitalo-Davies, Tissue Viability Nurse

BIRMINGHAM COMMUNITY HEALTHCARE NHS FOUNDATION TRUST

### CLINICAL CHALLENGE

Highly exuding wet leg with superficial ulceration and oedema. (Fig 1).

### THE PATIENT

This 76 year old lady was receiving treatment at home from the community nurses. Community nurses had been visiting this lady for the past 3 weeks to treat open wounds and manage the leg oedema. This lady originally presented with an extensive area of contact dermatitis to the gaiter region of the leg and small ulcer to the anterior aspect of the leg. Dressing changes had been taking place 3 x weekly with the dressing changes taking approximately 1 hour. The wound remained static, despite use of topical steroid therapy and compression hosiery, as exudate management was an issue.

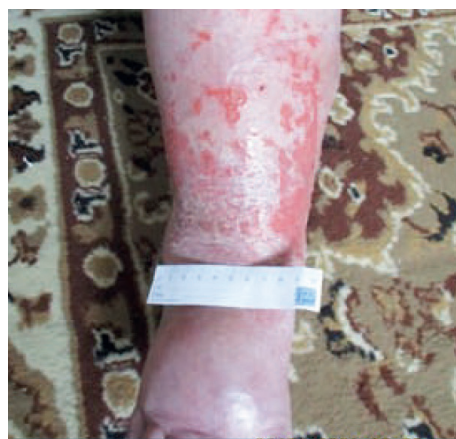
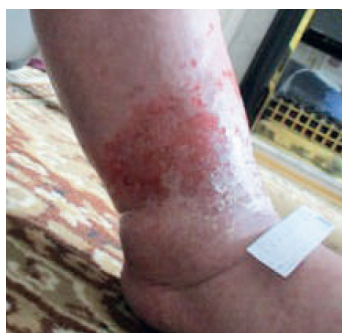
Fig 1. Right leg before treatment



### THE WOUND

The wounds to the leg, although clean and superficial were highly exuding and static for the past 3 weeks.

### MANAGEMENT AIMS

The overall aim for this leg was to reduce the oedema and in turn reduce the exudate levels to support the optimal environment for healing.

Treatment has been given in the form of compression hosiery to support this throughout. In order to further support the optimal environment, the aims for the wounds were:

- To manage exudate levels and prevent maceration to the surrounding skin
- Maintain healthy surrounding skin to prevent further wound breakdown
- Reduce dressing change frequency.

“  
Compression hosiery  
was used to support  
the treatment.  
”



## MANAGEMENT

Previously the leg had been treated with AQUACEL® Extra™ dressing and Zetuvit® plus superabsorbent with the addition of Dermovate ointment for the surrounding skin. Compression therapy was also being applied in the form of compression hosiery.

The community nurse changed the dressing regime to use ConvaMax™ Superabsorber as secondary dressing with AQUACEL™ Ag+ Extra used as a primary dressing.

Anti-infective dressings were commenced at this point due to suspected Biofilm via visual assessment, in the ulcer on the anterior aspect of the leg (Fig 1).

## OUTCOME

The revised dressing regime was applied for 7 days with dressing changes continuing 3 x weekly and compression therapy remained in place. Over the 7 days the wounds improved with the majority of the open wounds healing (Figs 2 & 3). ConvaMax™ Superabsorber effectively managed the excess exudate in this wound. It is recognised that the AQUACEL® Ag+ Extra dressing helped to manage the bacterial burden which may have been contributing to increased levels of exudate. The improvement demonstrated how Hydrofiber® Technology with application of AQUACEL® dressing as a primary layer and ConvaMax™ Superabsorber worked together to maintain the optimal environment to support healing.

The dressings were considered to be more effective than the previous regime. The patient commented that the new dressings were more comfortable and reported a reduction in pain.

After 7 days the dressing regime was stepped down to AQUACEL® Foam Non Adhesive 10cm x 10cm dressing to cover the open wound area to anterior leg only. From this point, dressing changes were reduced to once weekly with complete healing achieved in 2 weeks.

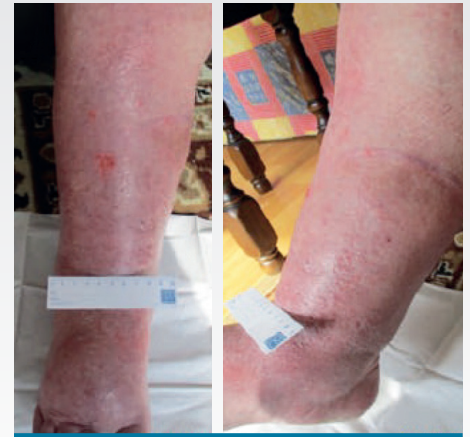

Fig 2. ConvaMax™ dressing in situ

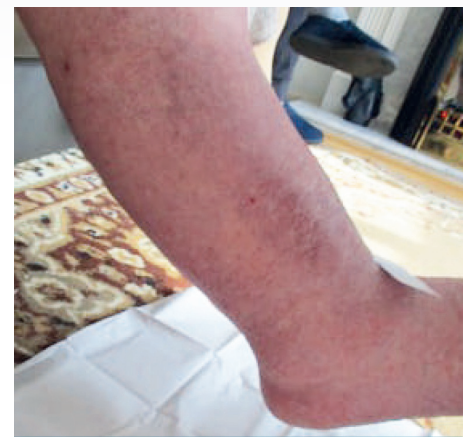

Fig 3. After 7 days treatment with ConvaMax™ Superabsorber and AQUACEL® Ag+ Extra dressings

“  
ConvaMax™ dressing managed the exudate better than Zetuvit® plus for this patient which improved the condition of surrounding skin.  
”



## Danielle Hartill, Lead Tissue Viability Nurse

WALSALL HEALTHCARE NHS TRUST

WITH SUPPORT FROM NORTH DISTRICT NURSE LOCALITY TEAM

### CLINICAL CHALLENGE

Highly exuding venous leg ulcer with Lymphoedema (Fig 1).

### THE PATIENT

This 64-year-old lady with slightly restricted mobility first presented on the district nurse case load with leg swelling, redness, and small wounds to the right leg 12 months ago. Since then, despite compression bandages the ulcers to the leg have deteriorated and four separate courses of antibiotics were required. For just over 12 months this lady has received daily visits using a wealth of different primary dressings including prolonged periods of antimicrobial products as well as conventional dressings.

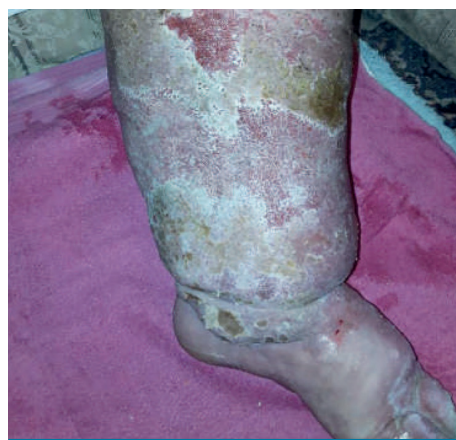
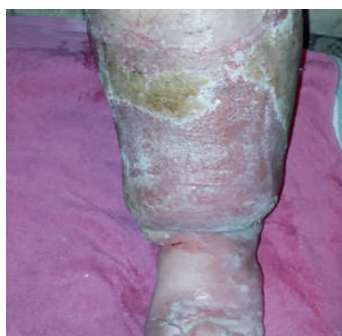
Fig 1. Right leg before treatment



### THE WOUND

The ulcers located on the right leg were proving hard to heal with areas of open superficial ulceration sporadic across the leg as well as large areas of macerated tissue and some areas of hyperkeratosis extending down to the toes (Fig 1).

### MANAGEMENT AIMS

The overall aim for this leg was to reduce the oedema and in turn reduce the exudate levels to support the optimal environment for healing.

Treatment has been given in the form of compression bandages to support this throughout.

In order to further support the optimal environment, the aims for the wounds were:

- To manage exudate levels and prevent maceration to the surrounding skin
- Maintain healthy surrounding skin to prevent further wound breakdown
- Reduce dressing change frequency
- Reduce odour that the patient was experiencing from the macerated tissue

“

The overall aim was to reduce the oedema and in turn reduce the exudate.

”



## MANAGEMENT

In the weeks prior to commencing ConvaMax™ Superabsorber the main treatment was Cutimed® Sorbion® Sachet pads for the leg and Kerramax Care™ across the foot. These superabsorbent dressings have been the main secondary products for the last 12 months with dressing changes for the most part daily and alternate days on adhoc basis. In addition, either antimicrobial or AQUACEL® Extra™ dressing was used between toes.

This dressing regime was swapped for ConvaMax™ Superabsorbent dressings with AQUACEL® Extra™ dressing continued to be used between toes.

## OUTCOME

Dressings continued daily initially. Within 3 days it was noted that there was less strikethrough of exudate and leg appeared to have improved as they were drier. The dressing change frequency reduced to alternate days or every third day.

DuoDERM® Extra Thin™ dressing was also commenced to some of the hyperkeratosis. The leg continued to show signs of improved skin condition (Fig 2 pictures from 1 week of the new dressing regime).

At 4 weeks (Fig 3) the leg had improved enough to reduce visits to twice a week.

By week 5 the District nurses had ordered a compression wrap to maintain the condition of this lady's leg. This patient was subsequently discharged from the District nurse caseloads.

ConvaMax™ Superabsorber dressings were considered more effective in managing the exudate than the previous regime. The patient commented that the new dressings were more comfortable and the new dressings didn't swell and drop down as the others often did.

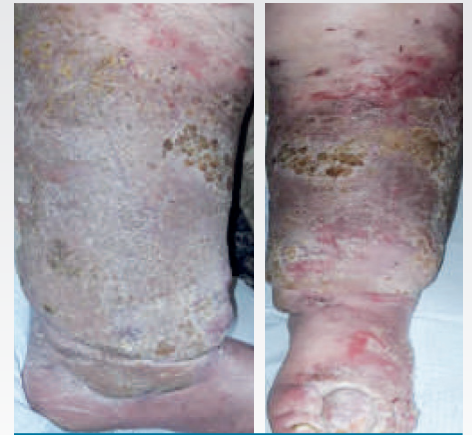

Fig 2. After 1 week of new dressing regime of ConvaMax™ Superabsorber and AQUACEL® Extra™ between toes the visits had reduced to alternate or every 3rd day

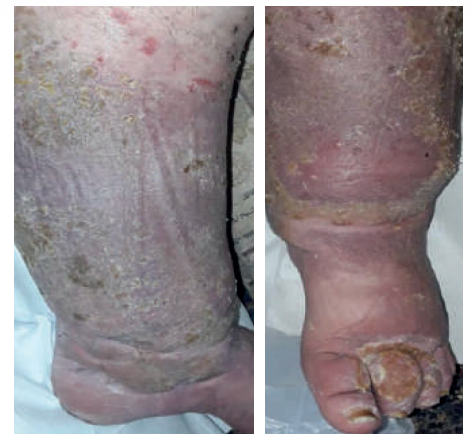

Fig 3. After 4 weeks of ConvaMax™ Superabsorber dressing visits were now reduced to twice a week

“

The nurses noted a change in this lady's mood as the exudate was managed better with the new regime and as legs continued to improve the patient started to go out more. Limb shape improved with the new dressing regime and it is thought this may be due to the conformability of the ConvaMax™ Superabsorber allowing the compression bandages to work more effectively.

”

# ConvaMax™ SUPERABSORBER



## Sebastian Kruschwitz, Certified Health and Nursing Care Worker and Wound Therapist

CENTER FOR VENTILATION AND INTENSIVE CARE  
ZBI GROUP, BERLIN

### CLINICAL CHALLENGE

A complex wound located on the sacral area of patient with an extensive medical history including ischaemic related co-morbidities and peripheral arterial occlusive disease (PAVD) (Fig 1).

### THE PATIENT

A 55-year-old patient with moderate general and nutritional health status, known to be a heavy smoker and alcohol abuser.

The patient has an extensive medical history including Ischaemia of both lower extremities,

- Peripheral arterial occlusive disease (PAVD)
- Cerebral arterial occlusive disease with high grade carotid artery stenosis (ACI)
- Spastic hemiparesis and hemiplegia

Such extensive vascular disease resulted in a mid-thigh amputation of the left leg.

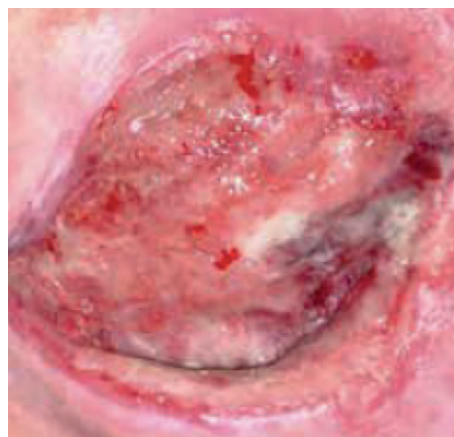

Fig 1. Sacral Pressure Ulcer before treatment

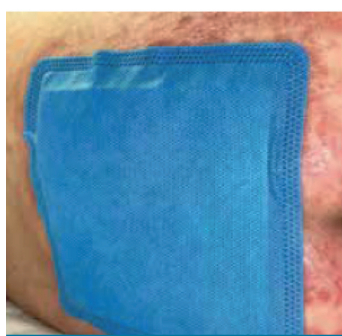

Fig 2. Application of ConvaMax™ Superabsorber dressing in combination with hyghtec® stool drain to prevent undermining by thin stool.

### THE WOUND

The patient presented with numerous wounds:

- Sacral Pressure Ulcer – category 4 of four months duration.
- Iliac crest right Pressure Ulcer – category 2.
- Iliac crest left Pressure Ulcer – category 3.
- Right Heel Pressure Ulcer – category 3.

*This case report focuses on the Sacral Pressure Ulcer (category 4) of 4 months duration (Fig 1).*

### MANAGEMENT AIMS

- Control of (particularly challenging) exudate due to clostridial infection.
- Reduction of the frequent dressing changes.
- Stopping the progressive damage to the wound bed and the periwound skin.

“

One of the main aims was to economically control the exudate.

”



## MANAGEMENT

### Initial challenges:

- Anatomical location – sacral area.
- Due to clostridial infection – the patient passed this aggressive stools several times a day.
- Faecal incontinence – led to wound therapy in this patient with a pressure ulcer located in the sacral area was very difficult at first, as there was also a clostridial infection and the patient passed thin, aggressive stools several times a day. The faecal incontinence led to highly frequent dressing changes and severe damage to the surrounding skin.
- Conceivably poor blood circulation – occlusion of the upper leg arteries.

The patient was initially treated with ConvaMax™ Superabsorber (Fig 2), which proved to be very efficient for this patient with his multiple diagnoses, complex and challenging situation and to provide optimal wound care.

Frequent dressing changes were required due to thin stool, subsequently managed by a stool drainage system.\*

This approach gave confidence to ensure that the wound surrounding skin could stabilise and dressing change intervals adjusted to be more economically viable.

### Rationale for Dressing Choice:

- High performance with softness
- High absorption capacity
- Strong retention of wound exudate.

A considerable improvement with stabilisation and positive progression of the wound bed and margins were observed. It was evident that slough and superficial debris was removed from the wound bed and wound pockets relatively quickly.

Occasionally throughout the management regime, very high amounts of exudate were produced, hence AQUACEL® Extra™ dressing was used as a primary dressing in combination with ConvaMax™ as secondary dressing for a certain period of time (Fig 3).

Granulation tissue was able to regenerate very well under this treatment regime. The primary dressing of AQUACEL® Extra™ was loosely packed into the wound cavity to cover the entire wound bed. Using too much or too little dressing when filling a wound cavity is important to ensure the dressing is in contact with the wound bed at the base of the cavity. If an excessive amount of dressing is packed too tightly into the area as this may exert high pressure and have a detrimental effect on the formation of newly formed granulation tissue.

When too little material is used, excess exudate and cell debris cannot be absorbed by the wound filler and may cause damage to the periwound skin. Furthermore, there is also the possibility of the formation of a moist chamber, in which again bacteria/ pathogens can multiply that may lead to biofilm formation. Therefore, it is important to completely cover the wound bed, overlapping the wound edges and loosely drape any pockets/sinus tracts.

In addition to the dressing regime, the intestine was cleansed of Clostridium difficile by i.v. antibiotics and the sacral ulcer was surgically debrided. The wound continued to improve with notable reduction in depth and evidence of healthy granulation tissue on the wound bed (Fig 4).

The other two decubitus ulcerations on the right heel and the hallux valgus initially progressed very well and the devitalised tissue decreased. However, due to the sudden deterioration of the blood circulation, the patient had to be transferred to the clinical setting because there was a risk of sepsis.

Unfortunately, after initial improvement of the wounds of the right heel, due to sudden deterioration of the blood circulation, to avoid the death, a mid thigh amputation of the right leg had to be performed.

## OUTCOME

Through simultaneous sanitation of the Clostridium difficile and the surgical debridement, two factors that considerably limited the patient's quality of life could be eliminated. The superabsorbent ConvaMax™ dressing ensured very good exudate management in both parts of the therapy and thus supported positive wound progression and economic wound management.

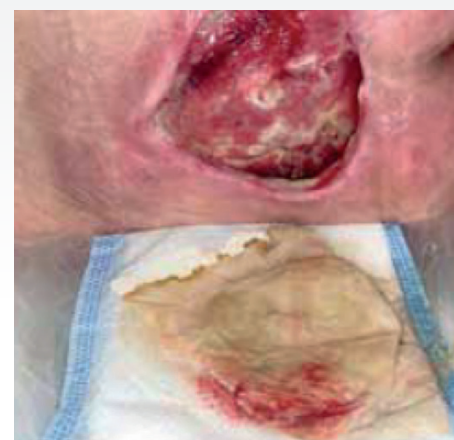

Fig 3. AQUACEL® Extra™ dressing was used in combination with ConvaMax™ Superabsorber for 14 days.

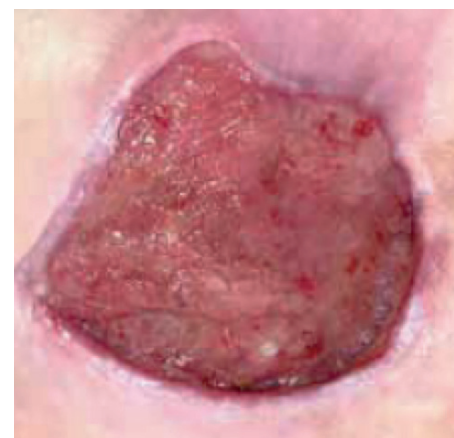

Fig 4. Notable reduction in wound depth and evidence of healthy granulation tissue on the wound bed.

“

Extended dressing change intervals brought an economic advantage and promoted wound healing.

”

\* Hyghtec®